



## PATIENT

Coca Jack Melendez

## SPECIES

Canine

## BREED

WHWT

## SEX

MN

## AGE

10 y

## WEIGHT

20.4 lb

## INTERPRETED BY

Keith Blass, DVM, MS,  
DACVIM (Cardiology)

## IMAGING PERFORMED BY

Dr. Gabriel Ferrer

## HOSPITAL NAME

Pulse Pet Ultrasound  
Services

## REFERRING VET

Dr. Trinidad

## INVOICE

## DATE

5/26/26

## PRESENTING CLINICAL SIGNS

Dry cough present at all times, but most frequent at night and when drinking water. Cough controlled with temaril P. PE – pulmonary crackles.

## ECHOCARDIOGRAPHIC FINDINGS

2D, M-mode, and Doppler study.

Left atrial size is normal. The mitral valve is normal. Left ventricular dimensions are normal. Left ventricular systolic function is hyperdynamic. The aorta and aortic valve appear normal, though there is very mildly increased flow velocity in the ascending aorta. Right atrial and right ventricular dimensions are normal. The tricuspid valve is normal. The pulmonary artery and pulmonic valve are normal. No shunting lesions are visualized. No heartworms are visualized. No pericardial effusion or cardiac masses are seen.

ECG during echo: Sinus arrhythmia

LA – 25.3 mm  
LVIDd – 28.0 mm  
LVIDs – 13.7 mm  
FS – 51%  
RA – 15.8 mm  
LVOT – 0.87 m/s  
RVOT – 0.83 m/s

## ASSESSMENT/RECOMMENDATIONS

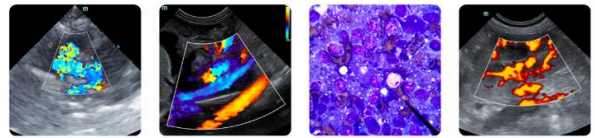
Normal echocardiogram

This examination demonstrates no evidence of structural heart disease. As such, no reason for Coca Jack's cough is appreciated in the image set.

No reason for Coca Jack's is appreciated in his radiographs, though the presence of pulmonary crackles suggests that inflammatory airway disease, pulmonary fibrosis, and what's more recently been described as non-specific interstitial pneumonitis in Westies, should be considered as possible differentials.

No therapy is recommended based on this exam.

A recheck echocardiogram is recommended if new physical exam and/or clinical abnormalities suggestive of the presence of cardiac dysfunction develop.



## PATIENT

Coca Jack Melendez

## SPECIES

Canine

## BREED

WHWT

## SEX

MN

## AGE

10 y

## WEIGHT

20.4 lb

## INTERPRETED BY

Keith Blass, DVM, MS,  
DACVIM (Cardiology)

## IMAGING PERFORMED BY

Dr. Gabriel Ferrer

## HOSPITAL NAME

Pulse Pet Ultrasound  
Services

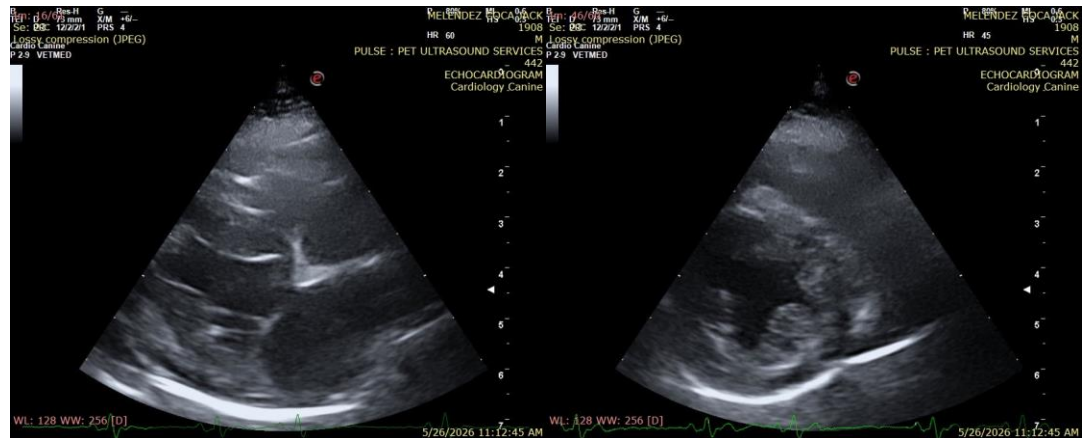
## REFERRING VET

Dr. Trinidad

## INVOICE

## DATE

5/26/26



The information and recommendations provided are based on the images presented by the referring veterinarian/sonographer. No evaluation can be communicated regarding pathology that was not visible in the image/video clips provided.

Thank you for this referral. If the clinical or image interpretation does not parallel your findings or if I can be of any further assistance please contact me.

Keith Blass, DVM, MS, DACVIM (Cardiology) [info@SonoPath.com](mailto:info@SonoPath.com)